

CREDIT VALLEY

THE CREDIT VALLEY HOSPITAL

PHYSICIAN'S ORDERS RENAL COLIC EMERGENCY MANAGEMENT

Allergies: _____

TO DELETE AN ORDER, DRAW ONE LINE THROUGH THE ITEM AND INITIAL

PART A - INITIAL MANAGEMENT

Nursing:

Dipstick urine
Instruct patient to filter urine

Medications:

IV normal saline TKVO **OR** _____ mL/h
Dimenhydrinate 25-50 mg IV q4h prn
Morphine _____ mg IV **STAT** then _____ mg IV q10min prn (maximum _____ mg/h) **OR** _____
Indomethacin 100 mg Suppository rectally x 1 **OR** indomethacin _____ mg po x 1

Labwork:

- Urinalysis
- Urine culture
- High risk patients:** CBC, electrolytes, urea, creatinine, glucose

Monitoring:

Vital signs, SaO₂ q15min before and during administration of narcotic

Additional Orders:

Date: _____ Time: _____

MD SIGNATURE

PART B - FOLLOWING REASSESSMENT at 2 hours

Pain resolved:
Helical CT scan in 1-2 days as outpatient
Followup with Family Physician or ER following scan
Prescription for analgesic (+/- NSAID)
Discharge instruction sheet, urine filter

OR

Pain NOT resolved:
 Helical CT scan (if available)
OR
 IVP (if no contraindications)
OR
 KUB and ultrasound

Date: _____ Time: _____

MD SIGNATURE

PART C - MANAGEMENT FOLLOWING IMAGING STUDIES

Admit patient to _____, MRP _____
Urology consult

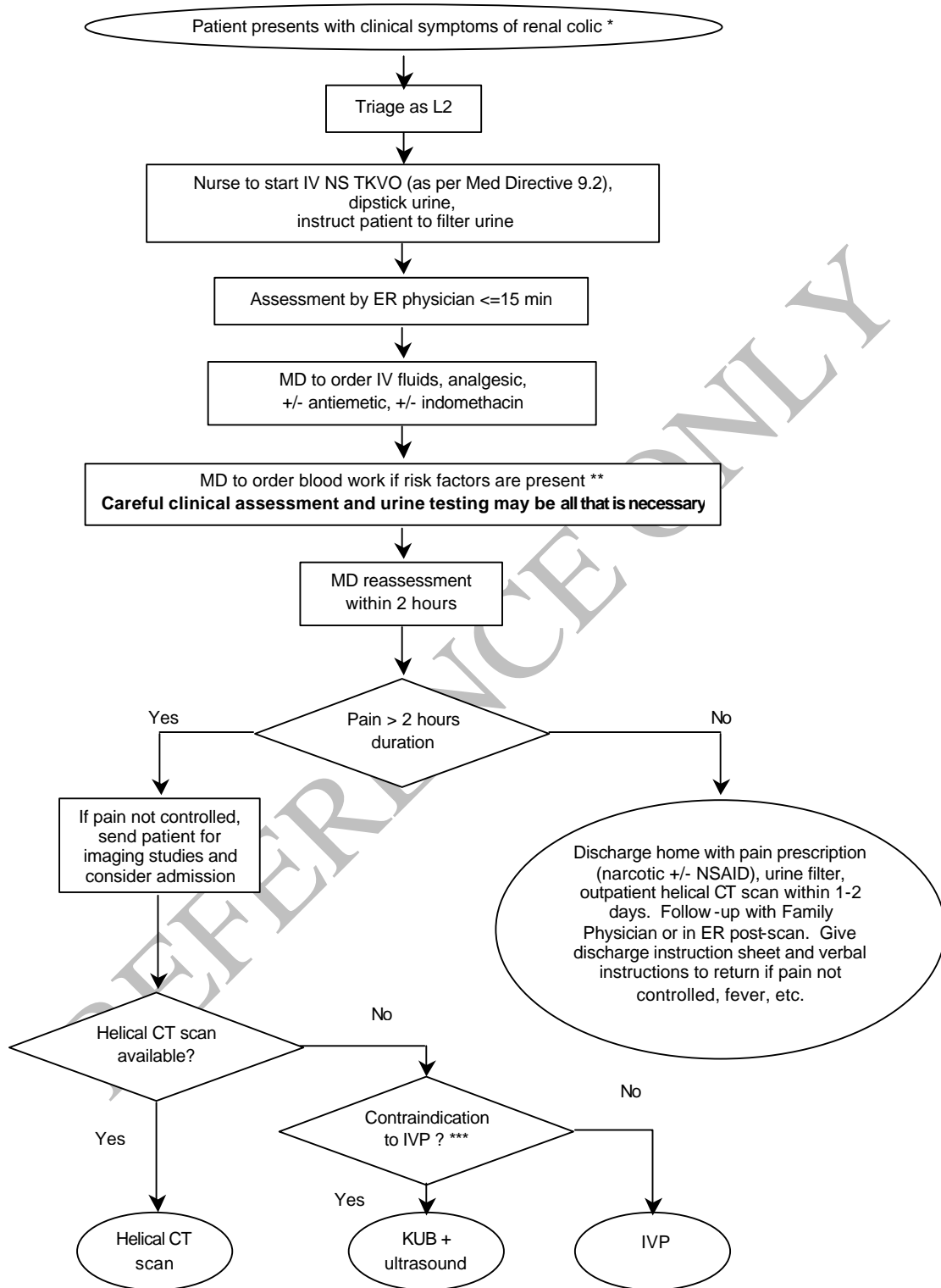
OR

Discharge patient, followup with Urology or Family Physician.
Prescription for analgesic (+/- NSAID)
Discharge instruction sheet, urine filter

Date: _____ Time: _____

MD SIGNATURE

MANAGEMENT OF RENAL COLIC IN THE EMERGENCY DEPARTMENT



* Usually young, previously healthy male, age 20 to 50, sudden onset of severe flank pain, +/- radiation, +/- nausea, with hematuria present in over 95% of cases. **Beware of the possibility of abdominal aortic aneurysm, renal cell or transitional cell carcinoma in the older patient.**

** Diabetes, hypertension, age>60, solitary kidney, immunosuppressed, coronary artery disease, CHF, severe liver disease.

*** Elevated BUN/creatinine, allergy to IVP dye. Consult radiology if patient on Metformin.

C R E D I T • V A L L E Y
 THE CREDIT VALLEY HOSPITAL
PHYSICIAN'S ORDERS
RENAL COLIC EMERGENCY MANAGEMENT

Allergies: _____

TO DELETE AN ORDER, DRAW ONE LINE THROUGH THE ITEM AND INITIAL

PART A - INITIAL MANAGEMENT

Nursing:

Dipstick urine
 Instruct patient to filter urine

Medications:

IV normal saline TKVO **OR** _____ mL/h
 Dimenhydrinate 25-50 mg IV q4h prn
 Morphine _____ mg IV **STAT** then _____ mg IV q10min prn (maximum _____ mg/h) **OR** _____
 Indomethacin 100 mg Suppository rectally x 1 **OR** indomethacin _____ mg po x 1

Labwork:

- Urinalysis
- Urine culture
- High risk patients:** CBC, electrolytes, urea, creatinine, glucose

Monitoring:

Vital signs, SaO₂ q15min before and during administration of narcotic

Additional Orders:

Date: _____ Time: _____

 MD SIGNATURE

PART B - FOLLOWING REASSESSMENT at 2 hours

Pain resolved:
 Helical CT scan in 1-2 days as outpatient
 Followup with Family Physician or ER following scan
 Prescription for analgesic (+/- NSAID)
 Discharge instruction sheet, urine filter

OR

Pain NOT resolved:
 Helical CT scan (if available)
OR
 IVP (if no contraindications)
OR
 KUB and ultrasound

Date: _____ Time: _____

 MD SIGNATURE

PART C - MANAGEMENT FOLLOWING IMAGING STUDIES

Admit patient to _____, MRP _____
 Urology consult

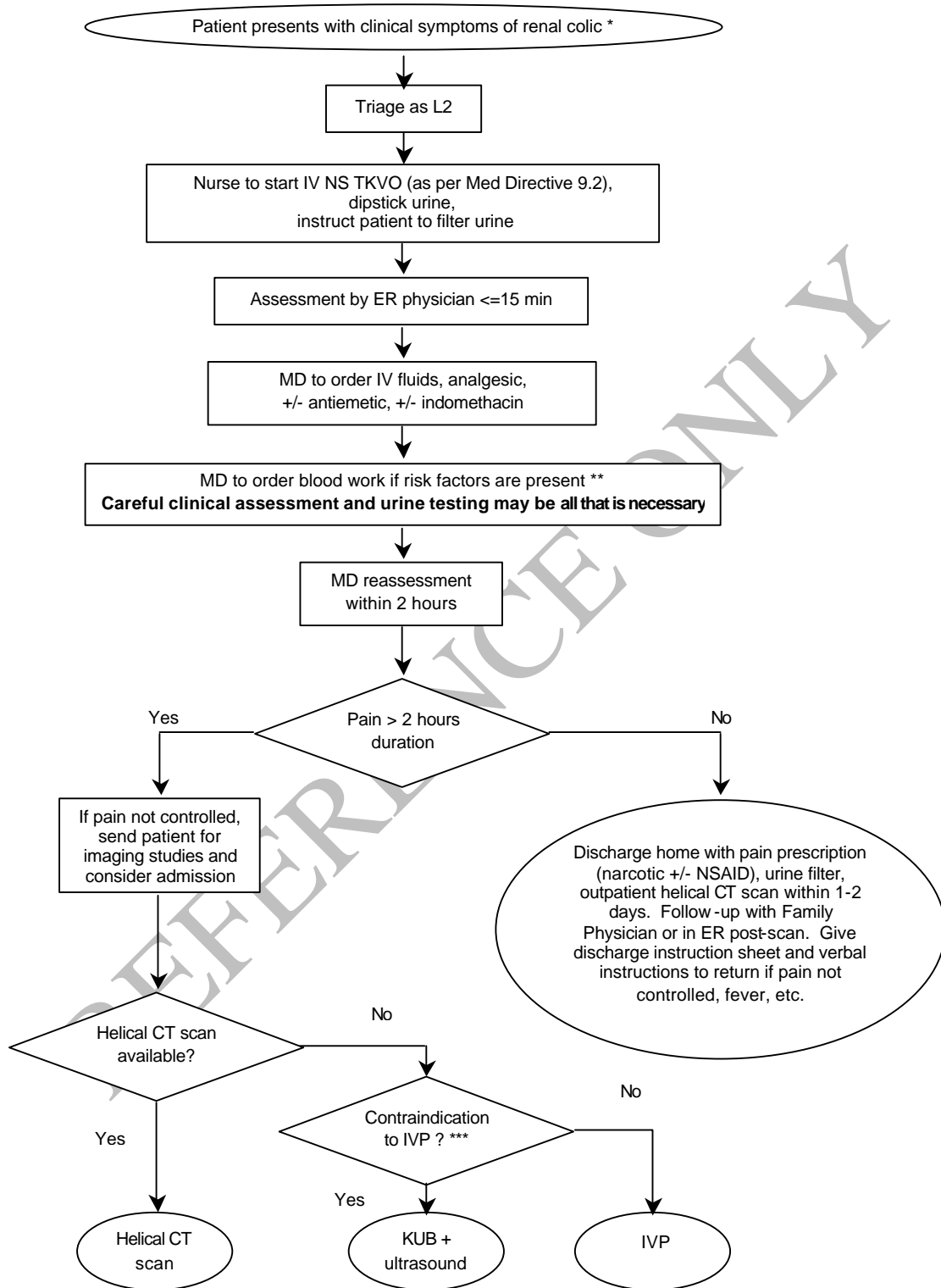
OR

Discharge patient, followup with Urology or Family Physician.
 Prescription for analgesic (+/- NSAID)
 Discharge instruction sheet, urine filter

Date: _____ Time: _____

 MD SIGNATURE

MANAGEMENT OF RENAL COLIC IN THE EMERGENCY DEPARTMENT



* Usually young, previously healthy male, age 20 to 50, sudden onset of severe flank pain, +/- radiation, +/- nausea, with hematuria present in over 95% of cases. **Beware of the possibility of abdominal aortic aneurysm, renal cell or transitional cell carcinoma in the older patient.**

** Diabetes, hypertension, age>60, solitary kidney, immunosuppressed, coronary artery disease, CHF, severe liver disease.

*** Elevated BUN/creatinine, allergy to IVP dye. Consult radiology if patient on Metformin.